



Pierre FAJADET

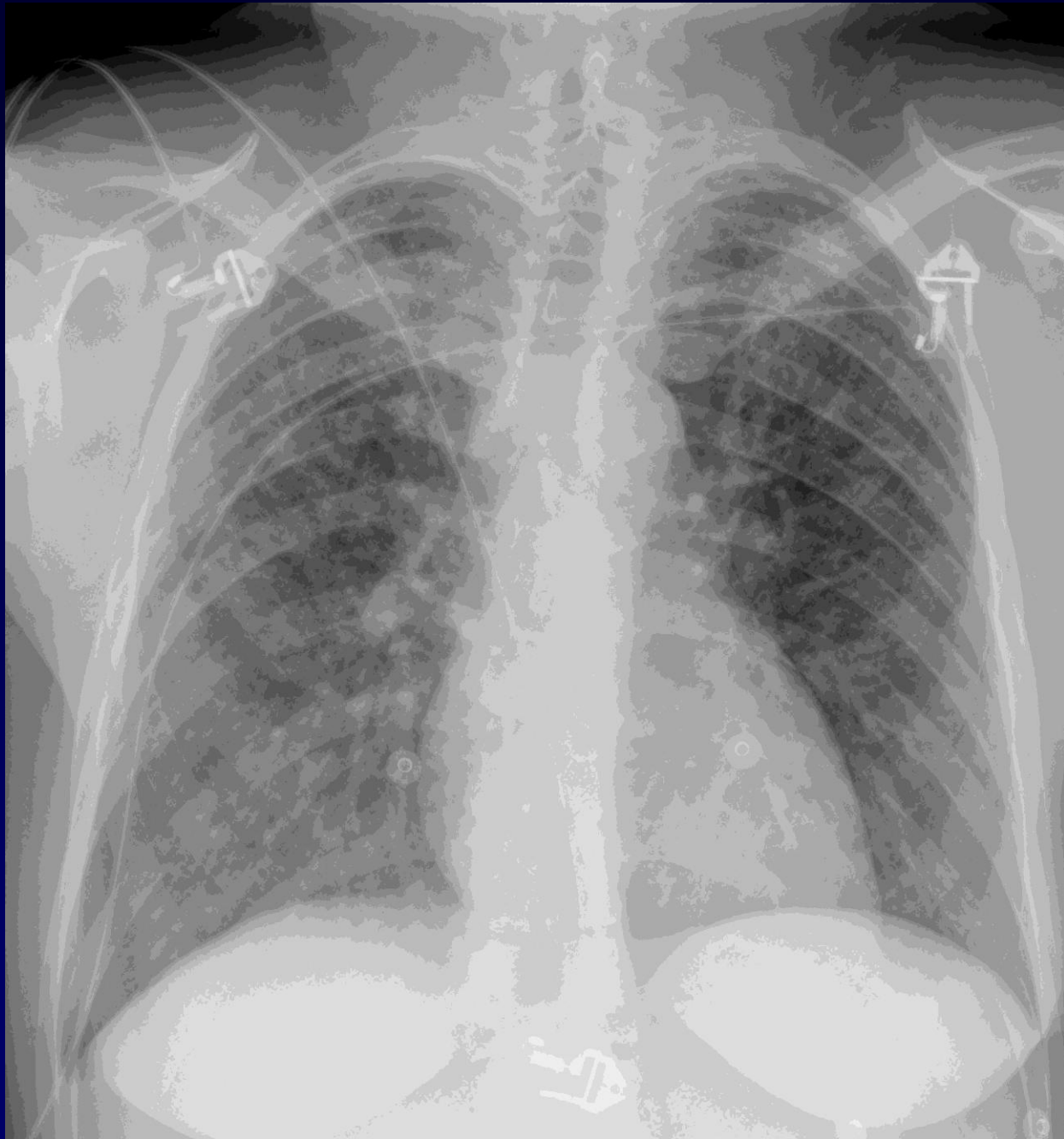
F, 32 ans

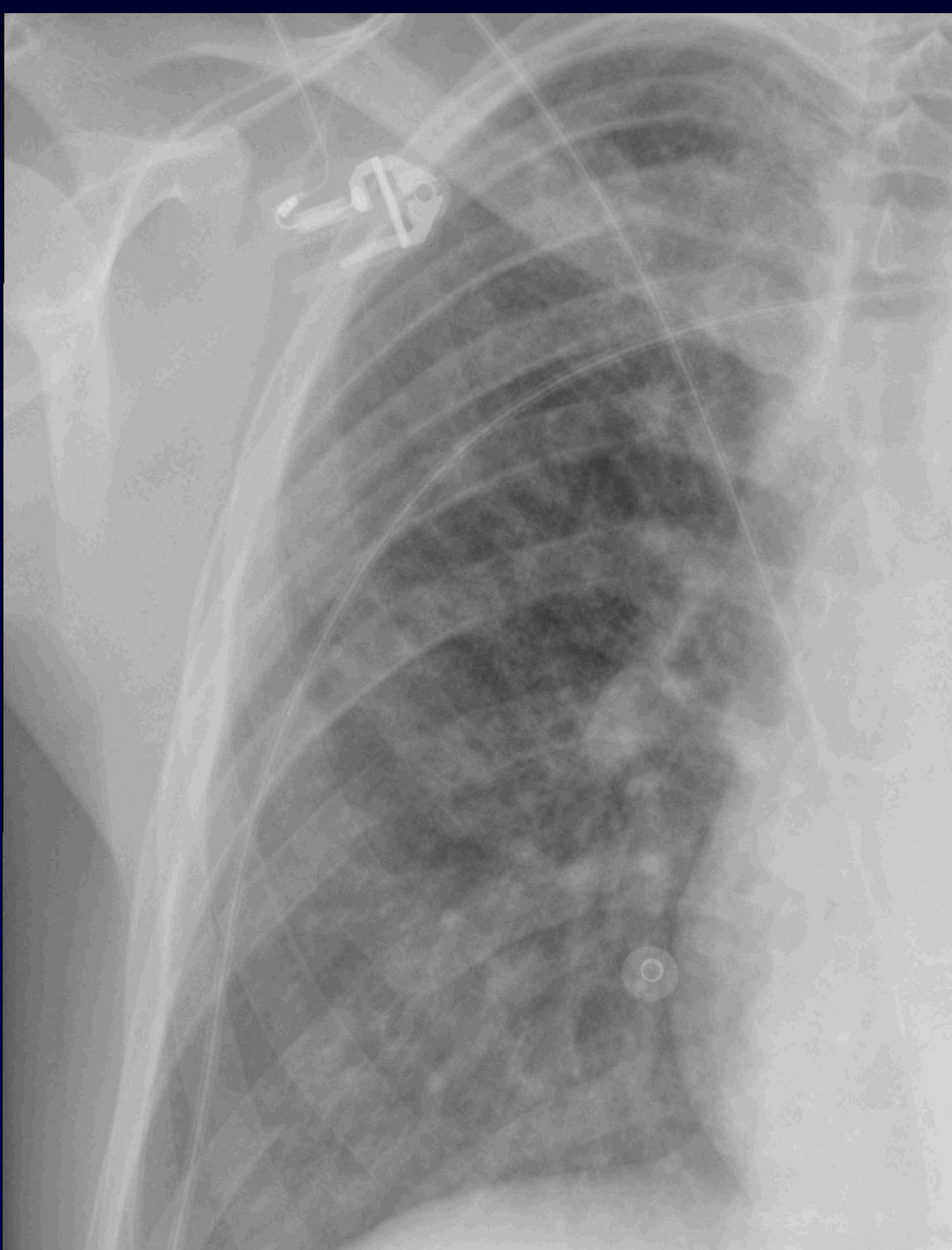
Cl: douleurs thoraciques

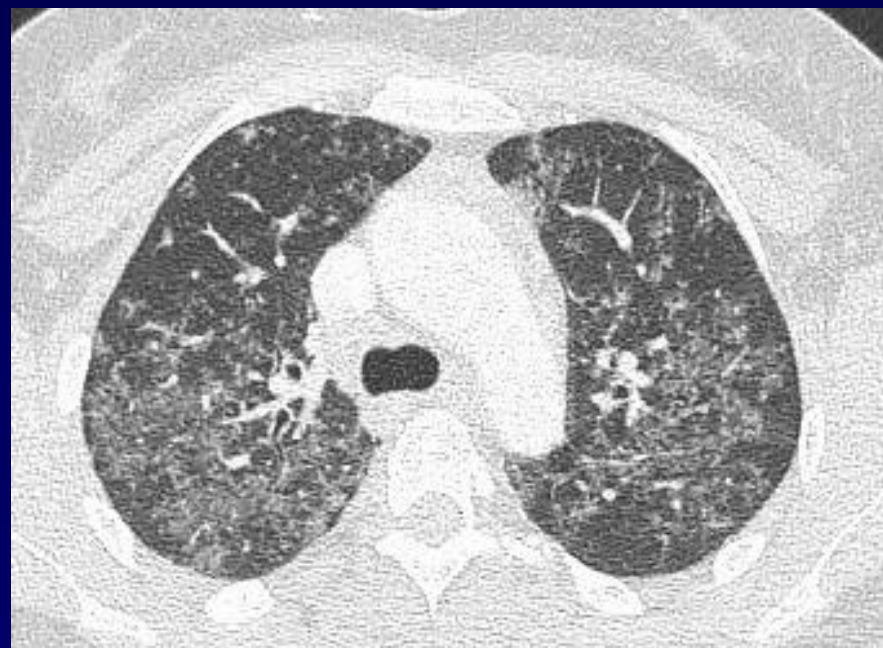
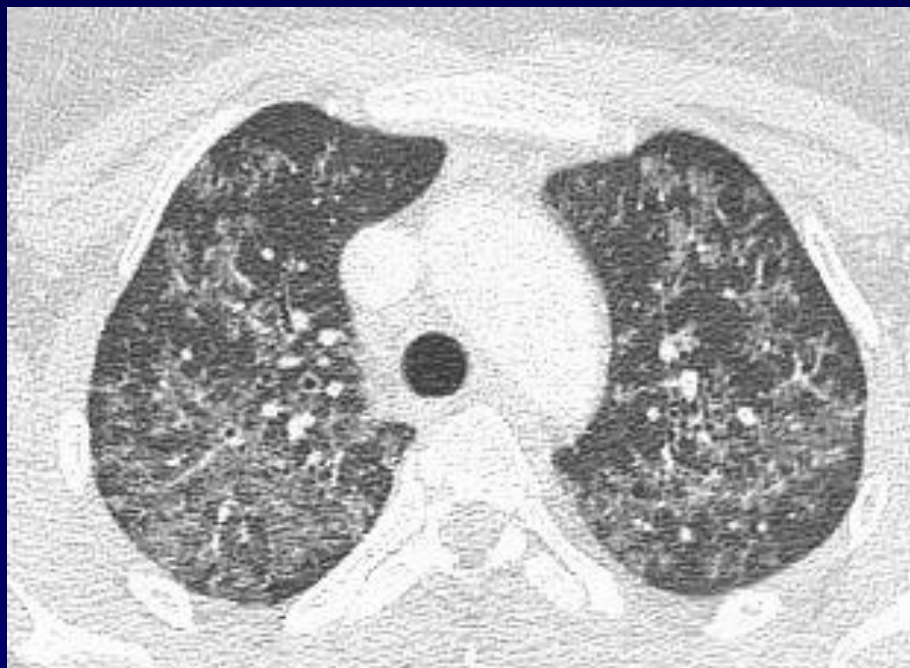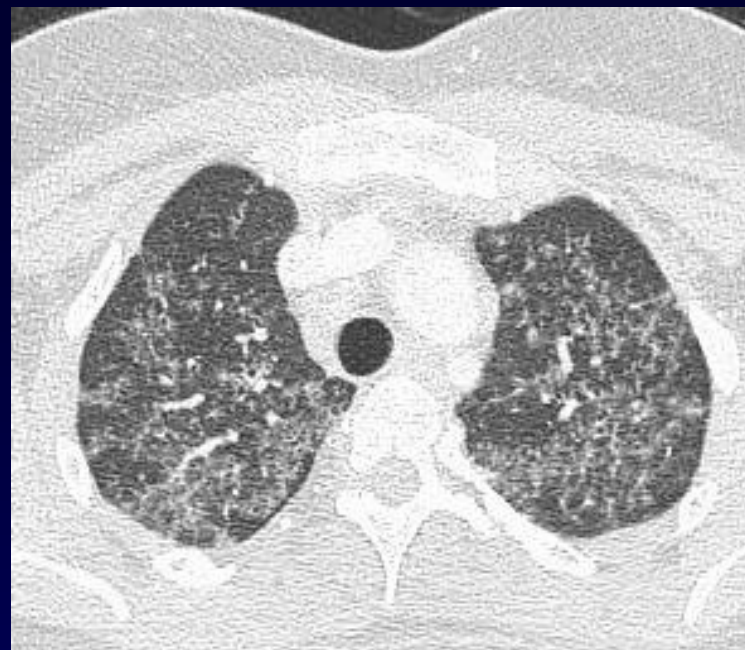
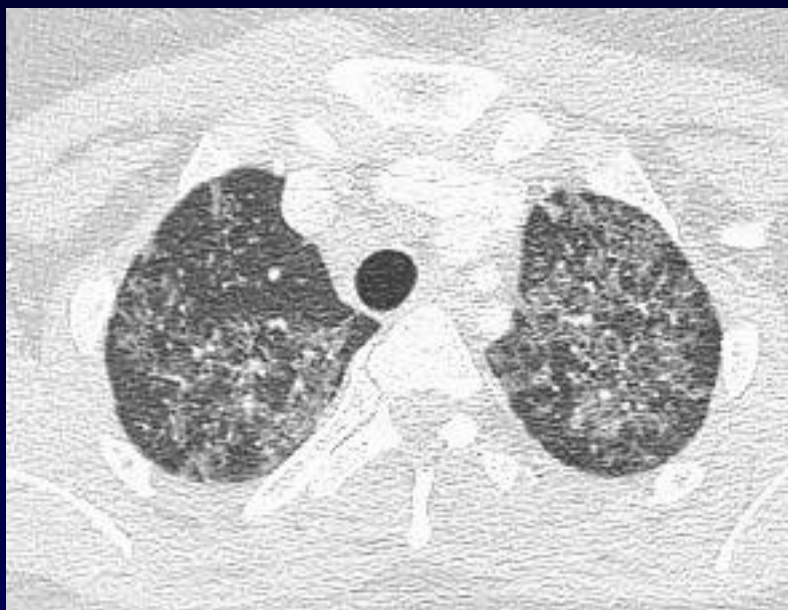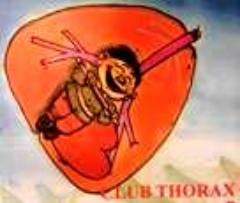pas de dyspnée, pas de toux, pas de fièvre

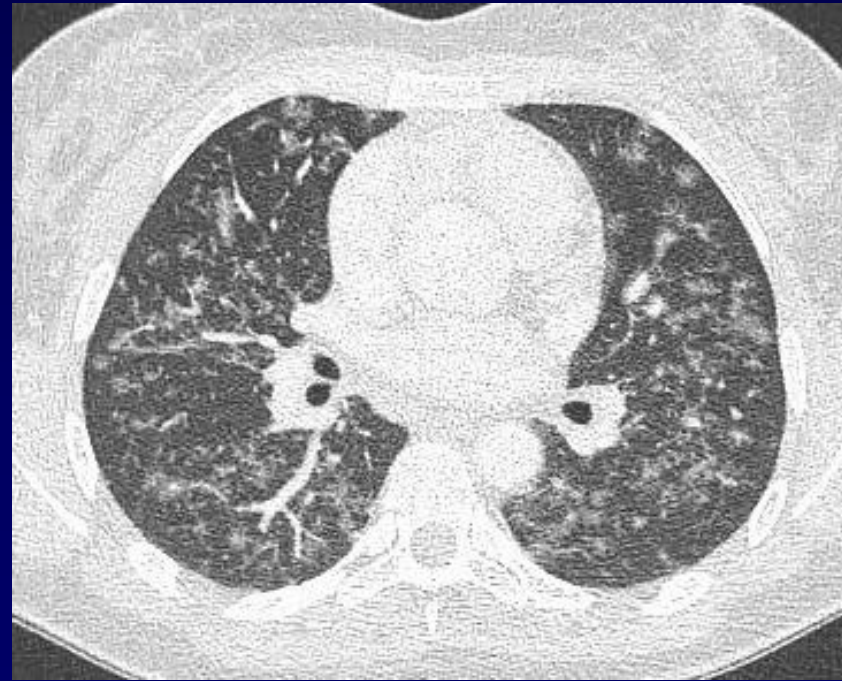
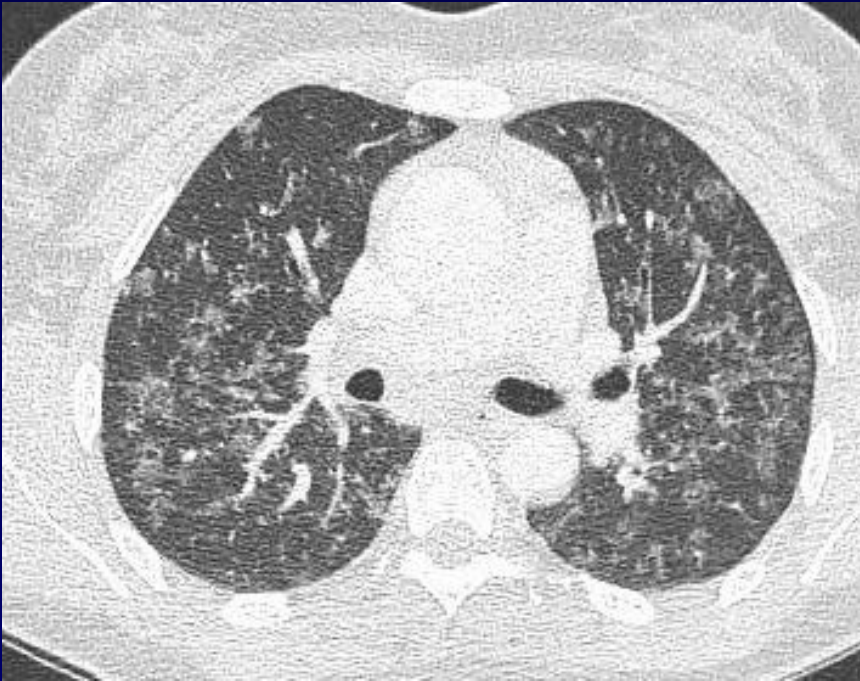
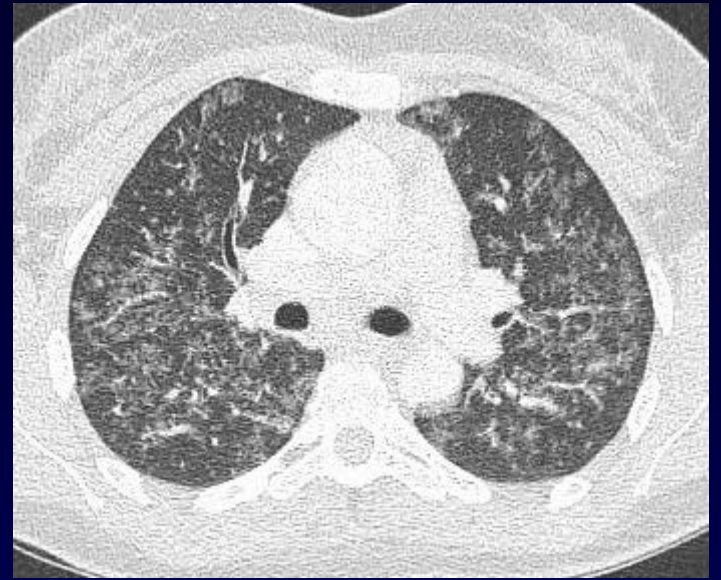
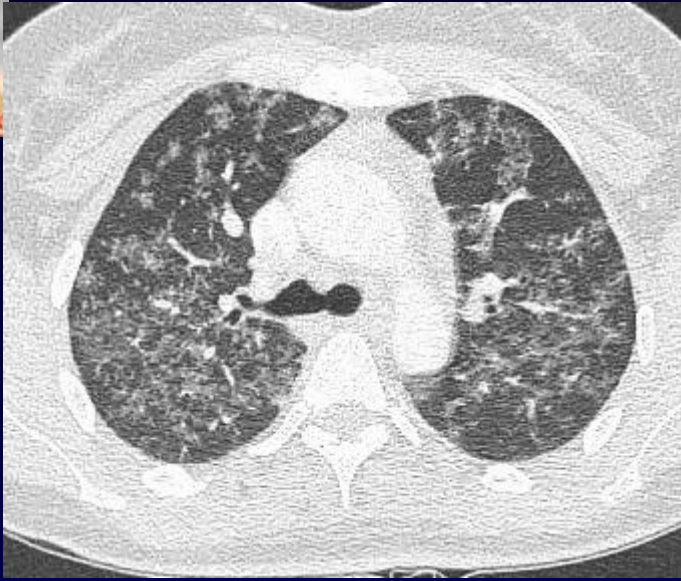
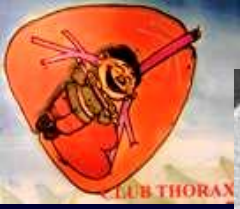ATCD: pas de tabagisme

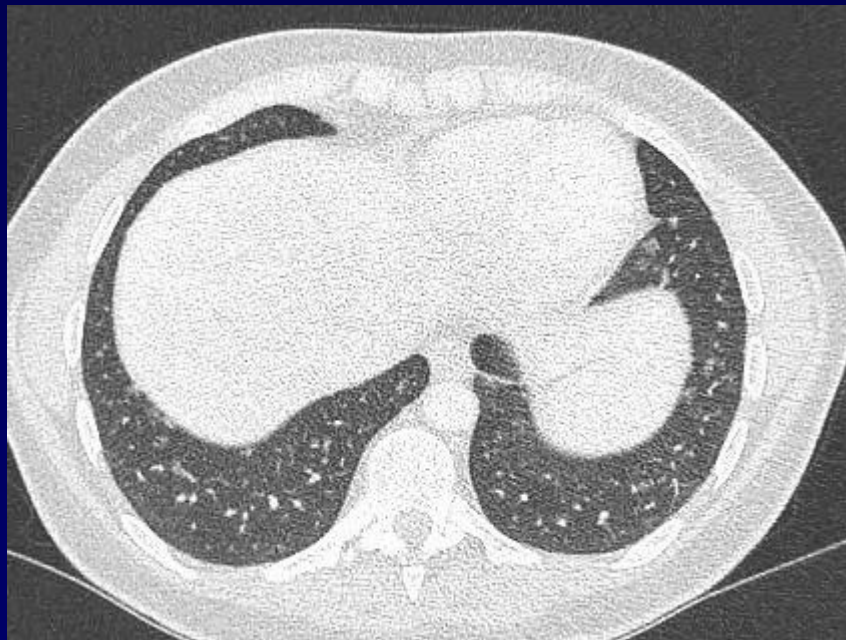
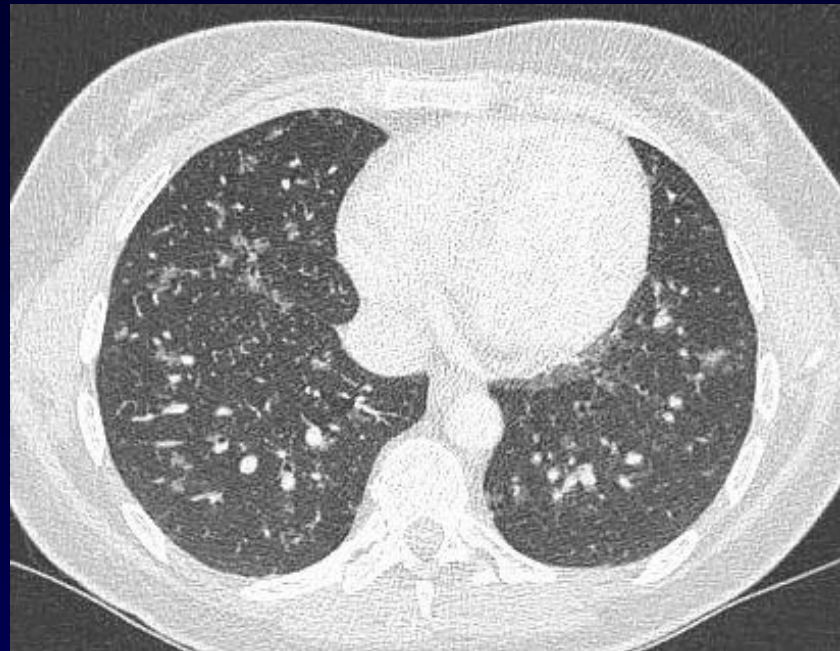
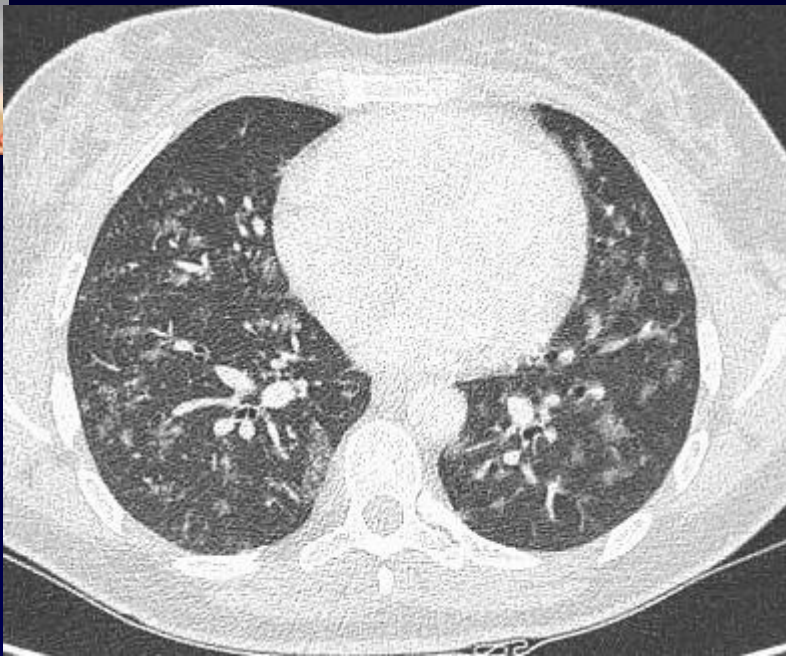
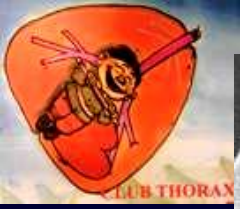uvéïte

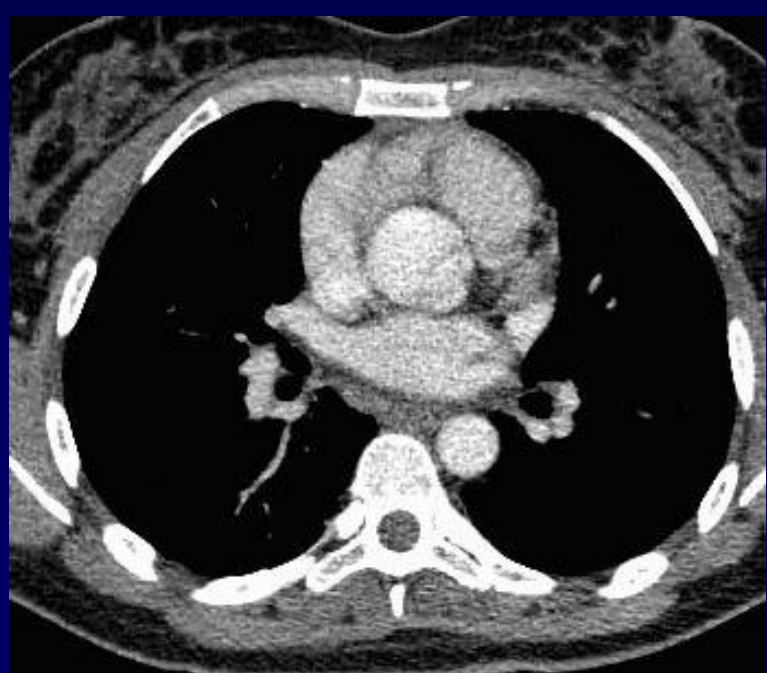
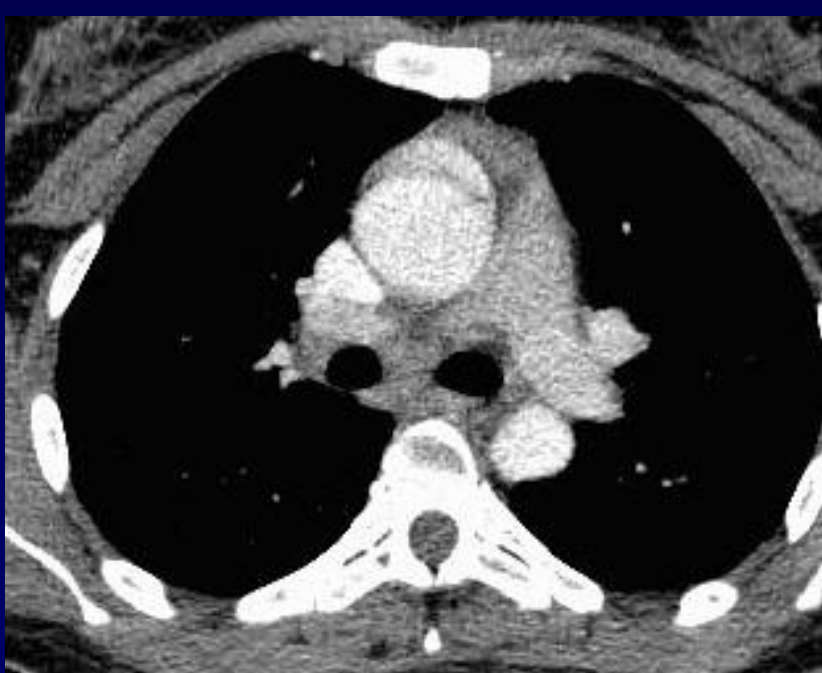
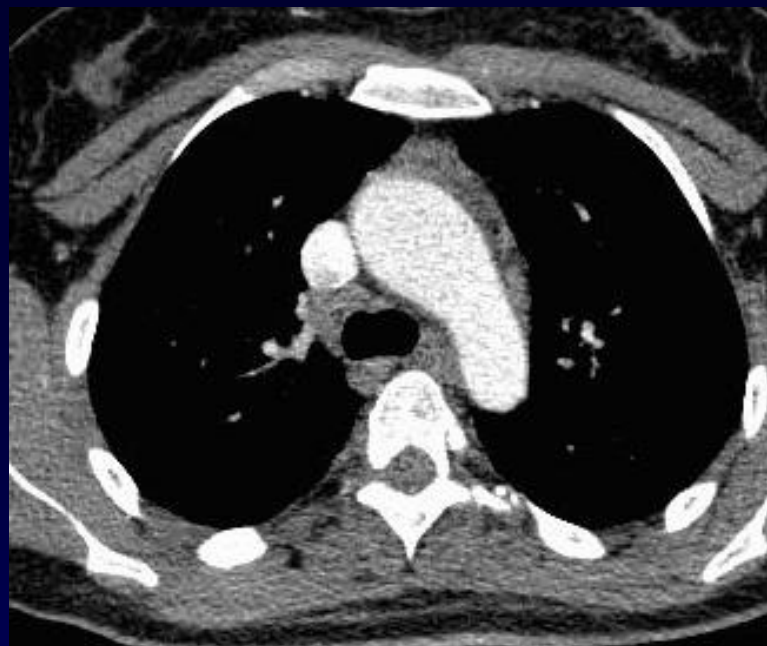
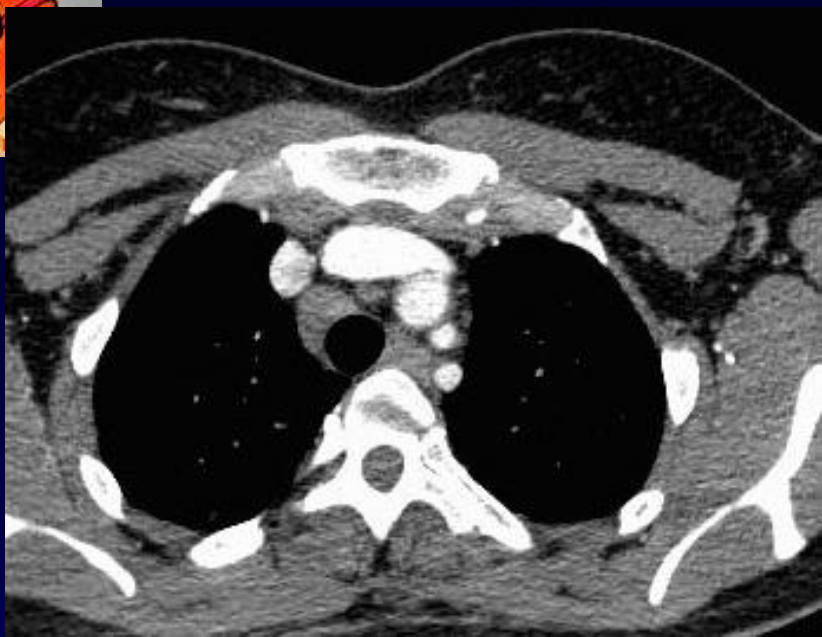


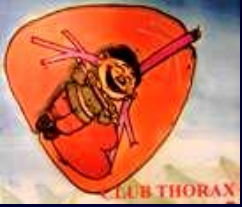








Bio: enzyme conversion sub normal

Endoscopie: RAS

LBA: Alvéolite lymphocytaire 28%

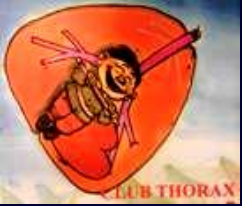**Biopsies bronchiques: Granulome épithélioïde
giganto-cellulaire sans nécrose caséuse**



Diagnostic ?



Sarcoidose



Sarcoidose et uvéite

**Rechercher une BBS devant toute uvéite,
même si non bilatérale et non
granulomateuse**

Elle préjuge d'une BBS sévère

Corticothérapie +++

Pronostic visuel souvent médiocre



Contrôle après 3 mois corticothérapie

